

Aminoglycoside Nephrotoxicity/ Induction of Nephrotoxicity by Gentamicin

M. Abirami*, M. J. Raja, P. Mekala and P. Visha

Department of Veterinary Pharmacology and Toxicology

Veterinary College and Research Institute - Namakkal

*Corresponding Author E-mail: abirami029@gmail.com

Received: 4.01.2019 | Revised: 12.02.2019 | Accepted: 23.02.2019

ABSTRACT

Gentamicin is an antibiotic that exhibits a broad spectrum of (Gram –ve) activity and is particularly valuable in several sepsis in animals and humans. Nephrotoxicity and ototoxicity has been recognized as a major complication of aminoglycoside antibiotics for many years. Gentamicin causes reversible renal impairment. The incidence of renal failure is 10-15 % (Naidu et al., 2000) and 10-20 % (Silan et al., 2007) of therapeutic courses. The present study aims at studying the nephrotoxic effect of gentamicin at one high dose (40 mg/kg). The 12 Wistar Albino rats were divided into 2 equal groups (Control and Gentamicin group). Plasma creatinine and BUN concentration was significantly increased as a result of nephrotoxicity. The clinical signs such as dullness, inappetance, increased water intake and increased urination was also observed. Proximal tubular necrosis, vacuolation, desquamation and degeneration in epithelial cells of the proximal tubules, hyaline casts in tubular lumen, mononuclear cell infiltration, glomerular and basement membrane alterations were histopathologically detected in kidney in gentamicin group. In conclusion, gentamicin has adverse effect in kidney.

Keywords: *Gentamicin, Nephrotoxicity.*

INTRODUCTION

Gentamicin is a cheap important and widely used antibiotic of aminoglycoside, derived from *Micromonospora purpurae*. It is used in life threatening gram negative infection. The chemical stability and rapid bactericidal action have made it a drug of choice in a variety of clinical situation. The major complication gentamicin is nephrotoxicity and ototoxicity. Gentamicin causes reversible renal impairment in 10-20 % of patients treated. The exact

mechanism of gentamicin induced nephrotoxicity is not clear. It has been shown to enhance the generation of reactive oxygen species (ROS). ROS have been suggested as the causative agent of cell death in different pathological condition including renal diseases /renal failure. The present work aimed to evaluate histological and biochemical alterations in gentamicin induced nephrotoxicity in rats.

Cite this article: Abirami, M., Raja, M.J., Mekala, P., & Visha, P. (2019). Aminoglycoside Nephrotoxicity/ Induction of Nephrotoxicity by Gentamicin, *Int. J. Pure App. Biosci.* 7(1): 581-584. doi: <http://dx.doi.org/10.18782/2320-7051.1012>

MATERIALS AND METHODS

Chemicals

Gentamicin Sulphate -40mg/ml was used in this study.

Animals

Twelve adult Wistar albino rats weighing approximately 150-200g and aged were used in this experimental study. Rats were provided from LAM (Laboratory Animal Medicine) unit, Madhavaram. The rats were housed in plastic cages and fed with *ad libitum* feed and water throughout the experiment.

Experimental design

Rats were divided randomly into 2 equal groups including six animals each.

Group I

Control group: NS (same volume of GS) S/C for 15 days.

Group II

Gentamicin sulphate: GS (40 mg/kg) S/C for 15 days.

Sample collection

The blood samples were collected intraocularly at week 1 and 2 for estimation of BUN and creatinine. After 2 weeks, the animals were sacrificed and kidneys were collected for histopathological analysis.

The kidney of animals in which mortality noticed due to induction of

nephrotoxicity was used for histopathological analysis.

Biochemical analysis

The level of BUN and creatinine was estimated using Autospan[®] diagnostic kit. The BUN and creatinine was estimated by DNPH colorimetric method (Reitman & Frankel, 1957).

Statistical analysis

The mean values of different group were presented as Mean \pm SE difference between the mean values were estimated using one way ANOVA.

RESULT AND DISCUSSION

Clinical Observations

Induction of nephrotoxicity by gentamicin showed reduced activity, reduced feed intake and increased water intake in rats. Reduced activity and concentrated urine output may be due to the occurrence of renal dysfunction. Loss of appetite, anorexia, increased catabolism and acidosis in gentamicin induced acute renal failure in rats may be the reasons for reduced feed intake (Erdem et al., 2000). Haemodilution may be involved in the fall of sodium value *via* excess water intake and/or increased production of endogenous water (Mohammed et al., 2016).

Table 1. Clinical observations in gentamicin induced nephrotoxicity in rats

General Parameters Studied	During acclimatisation period (15 days)	During induction of nephrotoxicity (15 days)
Activity	Normal	Dull
Feed intake	Normal	Reduced
Water intake	Normal	Increased
Urine	Normal urine	Concentrated urine

Biochemical alterations

The mean BUN and Creatinine value of treatment groups are presented in Table 2 and Table 3 respectively. The significant increase in plasma BUN and creatinine when compared with control group indicate the occurrence of nephrotoxicity. The plasma creatinine concentration is more potent indicator than the urea concentration in first phase of kidney diseases. Urea (Yaman, I and E. Balikci, 2010)

concentration begins to increase only after parenchyma tissue injury (Gilbert et al., 1989).The elevated BUN is due to protein catabolism. The high level of blood urea noted due to increase breakdown of tissue or impaired excretion. There is increase in BUN and creatinine level after kidney fail to remove them and other waste products from blood (Mohamed et al., 2011).

Table 2. Effect of Blood Urea Nitrogen (mg/dL) (MEAN±S.E) in gentamicin induced nephrotoxicity in rats (n=6)

Week	T ₁	T ₂
Week 1	32.17 ^a ± 0.31	56.50 ^b ± 1.23
Week 2	30.17 ^a ± 0.54	71.67 ^b ± 1.65

Table 3. Effect of Creatinine (mg/dL) (MEAN±S.E) in gentamicin induced nephrotoxicity in rats (n=6)

Week	T ₁	T ₂
Week 1	0.51 ^a ± 0.02	0.83 ^b ± 0.03
Week 2	0.52 ^a ± 0.02	1.18 ^b ± 0.08

Histopathological alterations

Histopathological analysis showed that there was significant increase in renal damage in gentamicin treated groups. Sections from control group showed normal histological structure of the glomeruli and renal tubules in the cortex and normal tubules in medulla (Abdel-Raheem et al., 2009) and it is presented in Figure 1.

The histopathology of kidney from gentamicin treated rats is presented in Figure 2. It displayed necrosis and desquamation of

the tubular epithelial cell in renal cortex (Kaloyanides & Pastoriza- Munoz, 1980). The proximal tubules showed degeneration of epithelial lining with disruption of their brush borders and presence of epithelial debris in lumen the renal corpuscles showed degeneration of in glomerulus and disputed Bowmans capsules vacuolation and mononuclear cell infiltration (Azab et al., 2014). The finding of present study is similar to above findings.

Histopathology of kidney

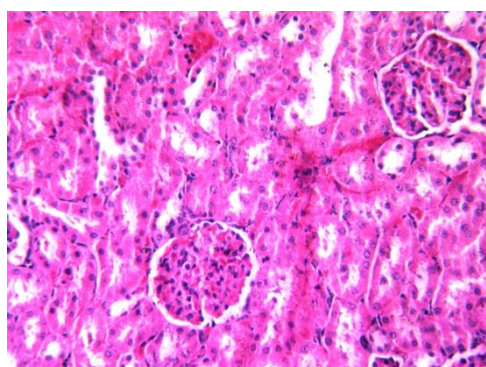


Figure 1. Kidney parenchyma comprise of tubules and glomeruli. H&E: 40x

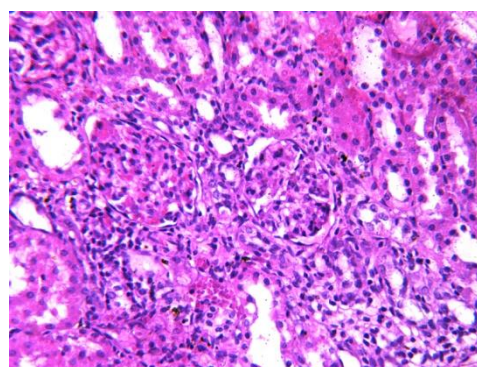


Figure 2. Kidney showing severe necrosis, diffused mononuclear cell infiltration and tubular dilatation. H&E: 40x

CONCLUSION

According to this study the clinical observations, biochemical and histopathological changes reveal that the gentamicin induces nephrotoxicity. Many herbs such as curcumin, rosemary, *Nigella*

sativa, *Ginkgo biloba*, garlic and *Tecoma stans* found to have nephroprotective effect against gentamicin induced nephrotoxicity. The use of aminoglycosides antibiotics must be regulated by administering it for specifically required cases after doing ABST or MIC. The

unwanted usage of aminoglycoside antibiotics must be avoided or may be used by combining it with some nephroprotective drugs or herbs.

REFERENCES

- Abdel-Raheem, I.T., A.A. Abdel-Ghany and G.A. Mohamed, (2009). Protective effect of quercetin against gentamicin-induced nephrotoxicity in rats. *Biol. Pharm. Bull.*, 32(1): 61-67.
- Azab, E.S., F.A. Fetouh and M.O. Albasha, (2014). Nephro-protective effects of curcumin, rosemary and propolis against gentamicin induced toxicity in guinea pigs: Morphological and biochemical study. *American Journal of Clinical and Experimental Medicine*, 2(2): 28-35.
- Erdem, A., N. Gundogan, U. Alp and A. Kara, (2000). The protective effect of taurine against gentamicin-induced acute tubular necrosis in rats. *Nephrol. Dial. Transplant.*, 15: 1175-1182.
- Gilbert, D.N., C.A. Wood, P.W. Kohlepp, D.C. Houghton, H.C. Finkbeiner, J. Lindsley and W.M. Bennet, (1989). Polyaspartic acid prevents experimental aminoglycoside nephrotoxicity. *Infect. Dis.*, 159: 945-953.
- Kaloyanides, G. J. and E. Pastoriza-Munoz, (1980). Aminoglycoside nephrotoxicity. *Kidney International*, 8: 571 -582.
- Mohamed, F., F. Bayomy, E. Sobhy, H.E. Naby, T.A. Salem and G.M. Salem, (2011). Protective role of curcumin on gentamicin induced renal toxicity in male albino rats. *Egypt. J. Exp. Biol. (Zool.)*, 7(1): 63 – 69.
- Naidu, M.U.R., A.A. Shifow, K.V. Kumar and K.S. Ratnakar, (2000). *Ginkgo biloba* extract ameliorates gentamicin-induced nephrotoxicity in rats. *Phytomedicine*, 7(3): 191-197.
- Reitman, S and S. Frankel, (1957). A colorimetric method for the determination of BUN and creatinine. *Am. J. Clin. Pathol.*, 28: 56-63.
- Silan, C., O.U. Kun, N.U. Comunoglu, S. Gokcen, S. Bedirhan and M. Cengiz, (2007). Gentamicin-induced nephrotoxicity in rats ameliorated and healing effects of resveratrol. *Biol. Pharm. Bull.*, 30(1): 79-83.
- Yaman, I and E. Balikci, (2010). Protective effects of *Nigella sativa* against gentamicin-induced nephrotoxicity in rats. *Experimental and Toxicologic Pathology*, 62: 183-190.